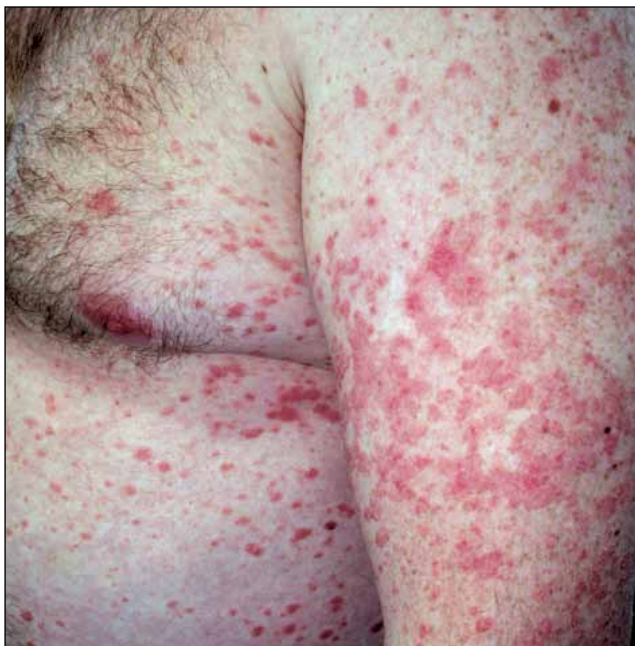

---

## Dermacase

---



### Can you identify this condition?

Olivia Potok MD Vimal Prajapati MD  
Benjamin Barankin MD FRCPC

**A** 30-year-old man presents with a 5-day history of a bilateral, symmetric eruption consisting of multiple, well-demarcated, scaly, erythematous, droplike papules primarily distributed over his trunk and extremities. He denies having any systemic symptoms, but does note that he had a sore throat approximately 2 weeks ago.

#### The most likely diagnosis is

1. Pityriasis rosea
2. Secondary syphilis
3. Nummular dermatitis
4. Guttate psoriasis
5. Pityriasis lichenoides

*Answer on page 56*

### Answer to Dermacase *continued from page 55*

#### 4. Guttate psoriasis

Guttate psoriasis is a distinct eruptive dermatosis that classically occurs in children and young adults following a group A  $\beta$ -hemolytic streptococcal (GAS) infection. Guttate psoriasis might present as either the initial manifestation of psoriasis in individuals previously unaffected by psoriasis or as an acute exacerbation in individuals with pre-existing chronic plaque psoriasis. Affected patients are much more likely to have a family history of psoriasis, and might report experiencing a stressful life event in close association with the guttate eruption.<sup>1</sup>

Guttate psoriasis typically presents as an acute bilateral, symmetric eruption consisting of multiple, well-demarcated, salmon-pink to erythematous, round to oval papules ranging in size from 1 mm to 10 mm in diameter. A fine silvery scale is often present on more established lesions. The distribution is primarily on the trunk and proximal extremities. The palms, soles, and face are usually spared. The rash is often asymptomatic, although some patients might report mild pruritus. The word *guttate* is derived from the Latin word *gutta*, meaning "drop," as the lesions can be likened to red drops splashed upon the skin.

There is a well-established association between guttate psoriasis and antecedent or concurrent GAS infection.<sup>2,3</sup> Typically, the GAS infection precedes onset of the guttate eruption by 1 to 3 weeks, and the patient might relate a history of recent upper respiratory tract infection, pharyngitis, or tonsillitis. There have also been several case reports of guttate eruptions following streptococcal perianal dermatitis in children.<sup>4</sup>

The exact pathophysiologic correlation between guttate psoriasis and streptococcal infection is not fully understood. It is postulated that the guttate eruption might result from an immune reaction to the streptococcal infection, usually in those with susceptible genotypes, particularly human leukocyte antigen-Cw\*0602.<sup>5,6</sup> Human leukocyte antigen genotypes might influence T-cell proliferation in response to streptococcal antigens (some of which have shown homology with human keratin) and thus might modulate the inflammatory response.<sup>7,8</sup>

Guttate psoriasis is usually a self-limiting process, especially in children, with full resolution occurring within 12 to 16 weeks without treatment. Limited information is available about the long-term prognosis of individuals with first-manifestation guttate psoriasis. However, data from 1 small study suggest that approximately 33% of patients with guttate psoriasis might eventually develop chronic plaque psoriasis.<sup>9</sup>

#### Diagnosis

Guttate psoriasis is essentially a clinical diagnosis. Throat or perianal bacterial cultures to test for


streptococcal infection might be performed, and elevated antistreptolysin O titre levels are common. The differential diagnosis includes pityriasis rosea, pityriasis lichenoides, small plaque parapsoriasis, nummular dermatitis, secondary syphilis, and viral or drug exanthem.

Pityriasis rosea can be differentiated from guttate psoriasis on the basis of morphology and arrangement. Lesions of pityriasis rosea tend to be oval with collarette scaling (ie, circumferential scale just inside the peripheral margin) and their long axes are oriented along skin-cleavage lines on the trunk, thus creating the classic "Christmas tree" pattern. In addition, pityriasis rosea often begins with the "herald patch," a solitary, large, oval to round, scaly, salmon-coloured or erythematous plaque that precedes the generalized eruption by several days. Pityriasis lichenoides differs from guttate psoriasis in that the eruptions are more often polymorphic (as lesions are present in various stages of evolution) and the papules are generally smaller than those observed in guttate psoriasis. Lesions of small plaque parapsoriasis are flatter and tend to appear as elongated fingerlike patches on the lateral aspects of the trunk, thus producing a characteristic digitate pattern. Nummular dermatitis preferentially involves the distal extremities, and plaques tend to be more coin-shaped and very pruritic; nummular dermatitis plaques are less numerous than those of guttate psoriasis. Secondary syphilis can closely resemble guttate psoriasis, and syphilis serology should be considered if the diagnosis is uncertain. Patients with secondary syphilis tend to have more systemic complaints; involvement of the palms, soles, and face is also common, a distribution pattern that is not usually seen with guttate psoriasis. Viral and drug exanthems should also be considered in the differential diagnosis, as guttate psoriasis can appear similar to these 2 entities, especially early in its course when there is minimal or no scaling. A careful history regarding recent illness or medication use can help to clarify the diagnosis.

#### Treatment

Although guttate psoriasis is normally a self-limiting process, adjunct therapeutic agents might be beneficial in expediting resolution. Topical agents including emollients, corticosteroids, vitamin D3 analogues, or coal-tar preparations might be effective, but they are cumbersome to apply on account of the large area of involvement. In prolonged cases of guttate psoriasis, resolution might be further accelerated with the use of ultraviolet therapy, particularly narrowband UVB phototherapy, although psoralen-UVA photochemotherapy can also be used. However, firm evidence for the efficacy of these various therapies in the treatment of guttate psoriasis is currently lacking.<sup>10</sup>

If there is evidence of persistent or untreated streptococcal infection, a course of appropriate antibiotics is

indicated; however, there might be no associated improvement in the guttate psoriasis after therapy.<sup>11,12</sup> Finally, there is some limited evidence that tonsillectomy might help to reduce frequently recurring or chronic guttate psoriasis associated with streptococcal tonsillitis, although controlled clinical trials have yet to be completed.<sup>13</sup> 

**Dr Potok** is a first-year dermatology resident at the University of Alberta in Edmonton. **Dr Prajapati** is a third-year dermatology resident at the University of Alberta. **Dr Barankin** is a dermatologist practising in Toronto, Ont.

#### Competing interests

None declared

#### References

- Naldi L, Peli L, Parazzini F, Carrel CF; Psoriasis Study Group of the Italian Group for Epidemiological Research in Dermatology. Family history of psoriasis, stressful life events, and recent infectious disease are risk factors for a first episode of acute guttate psoriasis: results of a case-control study. *J Am Acad Dermatol* 2001;44(3):433-8.
- Telfer NR, Chalmers RJ, Whale K, Colman G. The role of streptococcal infection in the initiation of guttate psoriasis. *Arch Dermatol* 1992;128(1):39-42.
- Whyte HJ, Baughman RD. Acute guttate psoriasis and streptococcal infection. *Arch Dermatol* 1964;89(3):350-6.
- Ulger Z, Gelenava T, Kosay Y, Darcan S. Acute guttate psoriasis associated with streptococcal perianal dermatitis. *Clin Pediatr (Phila)* 2007;46(1):70-2.
- Mallon E, Bunce M, Savoie H, Rowe A, Newson R, Gotch F, et al. HLA-C and guttate psoriasis. *Br J Dermatol* 2000;143(6):1177-82.
- Gudjonsson JE, Karason A, Antonsdottir A, Runarsdottir EH, Hauksson VB, Upmanyu R, et al. Psoriasis patients who are homozygous for the HLA-Cw\*0602 allele have a 2.5-fold increased risk of developing psoriasis compared with Cw6 heterozygotes. *Br J Dermatol* 2003;148(2):233-5.
- Sigmundsdottir H, Sigurgeirsson B, Troye-Blomberg M, Good MF, Valdimarsson H, Jonsdottir I. Circulating T cells of patients with active psoriasis respond to streptococcal M-peptides sharing sequences with human epidermal keratins. *Scand J Immunol* 1997;45(6):688-97.
- Baker BS, Brown DW, Fischetti VA, Ovigne JM, Porter W, Powles A, et al. Skin T cell proliferative response to M protein and other cell wall and membrane proteins of group A streptococci in chronic plaque psoriasis. *Clin Exp Immunol* 2001;124(3):516-21.
- Martin BA, Chalmers RJ, Telfer N. R. How great is the risk of further psoriasis following a single episode of acute guttate psoriasis? *Arch Dermatol* 1996;132(6):717-8.
- Chalmers RJ, O'Sullivan T, Owen CM, Griffiths CE. A systematic review of treatments for guttate psoriasis. *Br J Dermatol* 2001;145(6):891-4.
- Dogan B, Karabudak O, Harmanyeri Y. Antistreptococcal treatment of guttate psoriasis: a controlled study. *Int J Dermatol* 2008;47(9):950-2.
- Owen CM, Chalmers RJ, O'Sullivan T, Griffiths CE. A systematic review of antistreptococcal interventions for guttate and chronic plaque psoriasis. *Br J Dermatol* 2001;145(6):886-90.
- McMillin BD, Maddern BR, Graham WR. A role for tonsillectomy in the treatment of psoriasis? *Ear Nose Throat J* 1999;78(3):155-8.

— \* \* \* —