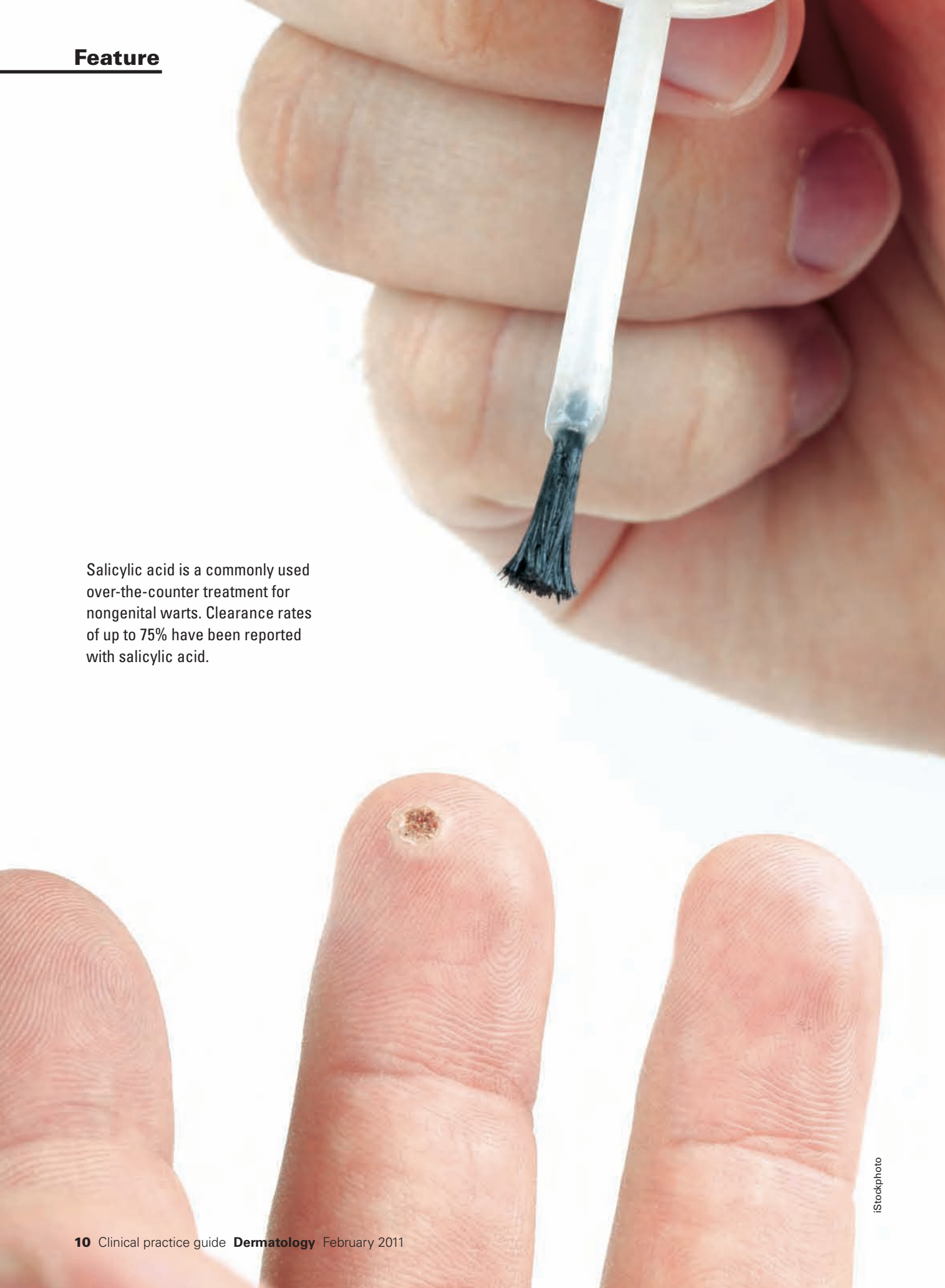


Feature

Salicylic acid is a commonly used over-the-counter treatment for nongenital warts. Clearance rates of up to 75% have been reported with salicylic acid.



The not-so-simple cutaneous wart

Lack of consensus on best treatments makes for a therapeutic challenge

by **Anil Kurian**, MD candidate in the class of 2011, Michael G. DeGroot School of Medicine, McMaster University, Hamilton
Dr. Benjamin Barankin, dermatologist and medical director of the Toronto Dermatology Centre

Cutaneous warts, one of the most common skin diseases, are a frequent presenting complaint to family practice and dermatology clinics. Common, plantar and flat warts are cutaneous manifestations of the human papillomavirus (HPV). Currently, more than 100 types of HPV have been identified. Certain HPV types tend to occur at particular anatomic sites; however, warts of any HPV type may occur at any site.

Warts are transmitted by direct or indirect contact, and predisposing factors include disruption to the normal epithelial barrier. While warts are not harmful and usually resolve spontaneously over time without any treatment, they are unattractive and can also be painful.

The treatment of warts poses a therapeutic challenge for physicians as no general consensus on monotherapy to achieve complete remission in all patients has been reached. As a result, many different approaches to wart therapy exist with varying mechanisms of action and efficacy.

Salicylic acid

Salicylic acid is a commonly used over-the-counter treatment for nongenital warts in adults and children. It causes desquamation of the infected tissue without affecting viable epidermis. Various preparations of salicylic acid are available commercially. Over-the-counter preparations are typically less than 17% salicylic

acid, whereas physician-prescribed preparations can contain as much as 70% salicylic acid. The skin is often soaked in water for five minutes and dried prior to application. For best results, the wart should be filed down. Treatment can continue for up to 12 weeks. Clearance rates of up to 75% have been reported. Adverse reactions consist of local irritation and discomfort, flaking and desquamation.

A 2006 Cochrane review led by Dr. Sam Gibbs, a dermatology consultant at the Ipswich Hospital in England, looked at pooled data from five randomized controlled trials (RCTs) and demonstrated a cure rate of 73% in those treated with salicylic acid, compared with 48% in the control groups. Most clinical guidelines list salicylic acid as the first-line therapy for flat warts on the face, plantar warts, and flat and common warts on the hands. The therapeutic benefit of topical therapies containing salicylic acid, whether over-the-counter or prescription, is supported by evidence from RCTs. There is consistent evidence that topical salicylic acid is an effective therapy for nongenital cutaneous warts.

Cryotherapy

Cryotherapy destroys warts by thermal cytolysis. It can be used to treat warts in any location. An experienced physician applies liquid nitrogen with a cotton applicator or cryospray.

Individual lesions and 2 mm to 5 mm of surrounding normal skin are frozen for up to 30 seconds. Some recommend that initial freezing should be followed by thawing and repeat freezing. Blistering usually occurs within 24 hours, followed by ulceration and healing within 10 to 14 days. Several treatments repeated at two- to four-week intervals are often necessary for clearance. As a result of pain associated with this technique, anesthetic may be used prior to therapy. Options include local anesthetic and topical lidocaine/prilocaine (EMLA) cream.

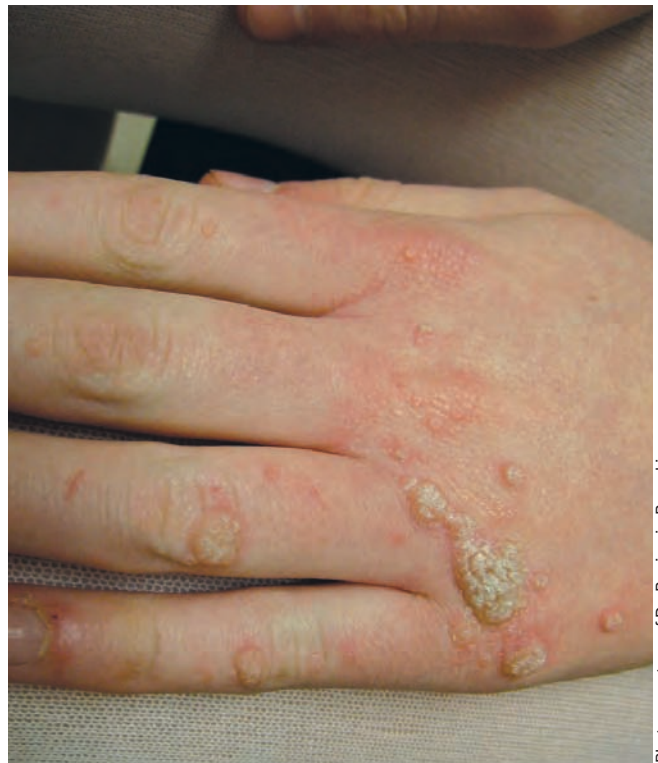Published clearance rates range from 50% to 70%, and recurrence rates range from 20% to 30%. In six-month followup studies, high recurrence rates of up to 70% have been reported. Adverse effects include pain and scarring. Cryotherapy is optimally used for patients with limited disease in any location.

A recent RCT by Dr. Sjoerd Bruggink and colleagues at Leiden University Medical Centre in the Netherlands looked at 240 patients in 30 primary-care practices presenting with new cutaneous warts. Patients were randomly allocated to one of three groups: cryotherapy with liquid nitrogen every two weeks, self-application of salicylic acid daily or a wait-and-see approach. The primary outcome was the proportion of patients whose warts were all cured at 13 weeks. Analysis was on an intention-to-treat basis. The results, published in the Oct. 19, 2010, edition of the *Canadian Medical Association Journal*, showed that for common warts (116 patients), cryotherapy was the most effective option, with a cure rate of 49%, compared with 15% in the salicylic acid group and 8% in the wait-and-see group. However, for plantar warts (124 patients), no clinically relevant difference in effectiveness was found between the three groups.

Podophyllotoxin

Podophyllotoxin is the active ingredient of podophyllin, which has antimitotic properties. It is effective in much lower concentrations than podophyllin and is available in 0.5% solution and 0.05% gel preparations. Podophyllotoxin is a treatment that patients can self-apply at home. The recommended regimen is application to lesions once or twice daily for a few days per week as tolerated. Application of podophyllotoxin can continue for up to four to six weeks if necessary. Correct application technique, as well as identification of treatable lesions, should be demonstrated by the physician. Clearance rates with the solution range from 45% to 75% with recurrence rates of 30% to 70%. To increase efficacy, the treatment is often combined with other destructive treatment options such as cryotherapy.

The most commonly reported adverse event is mild to moderate irritation, and less commonly pain, burning, pruritus, erosions and bleeding. Compared with podophyllin, this compound has a higher clearance rate, a more rapid healing time



Photos courtesy of Dr. Benjamin Barankin

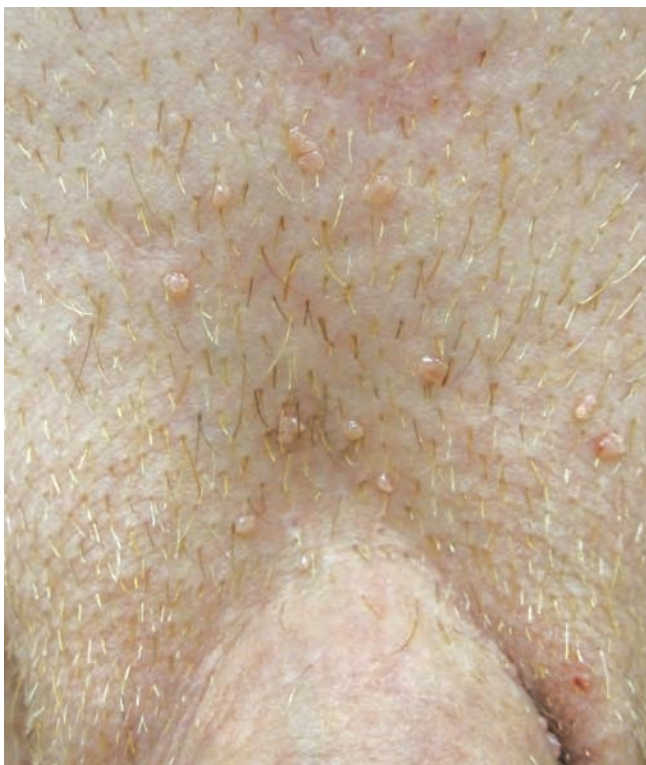Common warts usually appear on the hands. Those that grow around and under the nails tend to be more difficult to cure than warts found elsewhere.

and a lower potential for systemic toxicity. However, podophyllotoxin is limited in its use. The treatment area should be limited to less than 10 cm² and no more than 0.5 ml should be used per day. It is also not indicated for use in pregnant women or for perianal, vaginal or urethral warts, and does have a high cost associated with its use.

5-fluorouracil

5-fluorouracil (5-FU) is a chemotherapeutic agent that interferes with DNA and RNA synthesis. Both topical and intralesional compounds have been used to treat genital warts. The cream is applied in a thin layer one to three times each week. It should be washed off with soap and water after a few hours, depending on the location. Treatment can continue for several weeks. Studies have reported clearance rates of 41% to 68% in women, with recurrence rates of up to 10%. Adverse reactions include moderate to severe irritation. Several patients discontinued therapy as a result of irritation. Vaginal ulceration and an isolated case of vaginal adenosis with clear cell carcinoma have also been reported. Also, 5-FU is contraindicated in pregnant women due to its teratogenic potential.

For intralesional treatment, individual anogenital lesions are injected by the physician once weekly for up to six weeks.



Genital warts are highly contagious and are most common in younger adults, with most patients between the ages of 17 and 33 years.

Clearance rates that have been reported range from 55% to 77%. However, published recurrence rates are 58% at three months post-treatment and 70% at six months post-treatment. Adverse side-effects include pain with injection, local skin irritation and ulceration. Similar to topical application, intralesional 5-FU is contraindicated during pregnancy.

Imiquimod

Imiquimod 5% cream (Aldara) is a synthetic immunomodulatory agent that acts through the enhancement of both innate and cellular immune responses via extensive cytokine activation. It has been shown to be efficacious in treating external genital warts and is FDA-approved for use in children 12 and older. No large studies have been published on the safety and efficacy in children younger than 12 years of age, but case reports suggest the compound is both safe and highly effective in the treatment of genital warts in children as young as six months, with clearance rates of 75%. Treatment typically involves application of imiquimod 5% cream overnight three times weekly, with improvement within weeks to months. Side-effects, which are usually mild and well-tolerated, include local pain, pruritus and irritation. Because of the ease of application and the favourable side-effect profile, imiquimod is quickly becoming first-line treatment for condy-

loma in children.

As with podophyllotoxin, the correct technique should be demonstrated by the physician and the lesions to be treated should be indicated. Overall clearance rates range from 37% to more than 50% in patients who have failed other therapies. Erythema is the most frequent side-effect and has been considered by some to be a sign of efficacious treatment. Other less frequently reported reactions are pruritus, burning, edema and erosions.

Cantharidin

Cantharidin, a vesicant produced by beetles, has a long history of effective use in traditional medicine. In dermatology, topical cantharidin has been used as a vesicant for the treatment of warts and molluscum since the 1950s. The blistering reaction is focused within the epidermis and as such, scarring is generally not seen from this treatment. There is no pain from application of cantharidin, though blister formation can be painful. Cure rates have been reported to be as high as 80% for common, plantar and periungual warts.

Cantharone (0.7% cantharidin) is a topical medication that may be applied to plantar warts, allowed to dry, and covered for 24 hours. A blister forms after 24 to 72 hours which may be painful and take one to two weeks to heal. This treatment is not available over-the-counter and may be repeated every one to four weeks until resolution of the warts.

Zinc

Natural therapies, such as zinc, have also demonstrated some use in the treatment of warts. The effect of zinc on the immune system is well-known as deficiency in zinc causes lymphopenia and reduced immune capacity in humans. In microbial culture studies, addition of zinc can cause a polyclonal activation of lymphocytes. For these reasons, zinc is considered to be an immunomodulator and has been used successfully to treat many skin diseases with altered immune response. Gastrointestinal side-effects, such as dyspepsia, nausea and vomiting, are commonly associated with oral zinc therapy.

Limited evidence is emerging that zinc may be effective in selected populations with zinc deficiency. A placebo-controlled clinical trial was conducted in 1999 to 2000 in Iraq by

Topical cantharidin has been used as a vesicant for the treatment of warts since the 1950s. The blistering reaction is focused within the epidermis and as such, scarring is generally not seen from this treatment.

Prior to dispensing, tap the vial until powder flows freely. Add indicated amount of purified water to the vial (to the mark) and immediately shake to completely dissolve clindamycin. If needed, add additional purified water to bring level up to the mark. Add the solution in the vial to the gel and stir until homogenous in appearance (1 to 1 1/2 minutes). Reassemble jar with pump dispenser. BenzaClin® Topical Gel (as dispensed) can be stored between 15-25°C for 3 months. Place a 3-month expiration date on the label immediately following mixing.

OVERDOSAGE

Acute overdosage with the topical use of BenzaClin® Topical Gel (clindamycin, as phosphate, 1% and benzoyl peroxide 5%) is unlikely. If BenzaClin® is applied excessively, marked dryness, peeling and redness might occur. The literature indicates that clindamycin could be absorbed topically (see **WARNINGS AND PRECAUTIONS**). In the event of accidental ingestion, treatment should be symptomatic.

STORAGE AND STABILITY

Store BenzaClin® Topical Gel and its individual components between 15°C and 25°C (before and after reconstitution).

After reconstitution for dispensing to the patient, label BenzaClin® Topical Gel with a 3-month expiration date.

Do not freeze. Keep tightly closed. Keep out of the reach of children.

DOSAGE FORMS

BenzaClin® Topical Gel is dispensed in a 50-g jar equipped with a hand-actuated pump.

F.T. Al-Gurairi, a researcher at the Baghdad Teaching Hospital, and was published in the *British Journal of Dermatology* in 2002. Eighty patients with cutaneous viral warts resistant to treatment took part. All had a low serum zinc level. Forty patients were placed in an intervention group that received oral zinc at a dose of 10 mg/kg/day up to a maximum of 600 mg/day. The other 40 patients were given a placebo in the form of oral glucose pills. The primary outcome of the study was complete resolution of warts as well as any evidence of recurrence two to six months post-treatment. A total of 43 patients completed the study, 23 in the intervention arm and 20 in the placebo arm. Of the 23 patients in the intervention arm, 61% showed complete resolution of their warts at one month post-treatment and 87% showed resolution at two months. The resolution of warts was directly related to the rise in the serum zinc levels. No patients in the placebo arm had resolution of their warts.

Conclusion

The treatment of warts continues to pose a therapeutic challenge. Many different approaches to wart therapy exist with varying mechanisms of action and efficacy. The treatment options are extremely heterogeneous and no single treatment or group of treatments is standard. Patients are often dissatisfied with recurrence, as a therapeutic regimen to achieve complete remission in all patients has not yet been developed. The recent clinical trial showing cryotherapy as the most efficacious option to treat common warts in primary care will help direct physicians toward providing optimal therapy for patients. Additional clinical trials of the many therapeutic options will help to clarify the best treatment choices for cutaneous warts.

Disclosures

The authors have no conflicts of interest to disclose in relation to this article.

For further reading

1. Gibbs S, Harvey I. Topical treatments for cutaneous warts. Cochrane Database of Systematic Reviews 2006, Issue 3.
2. Bruggink SC, Gussekloo J, Berger MY, et al. Cryotherapy with liquid nitrogen versus topical salicylic acid application for cutaneous warts in primary care: Randomized controlled trial. *CMAJ*. 2010 Oct 19;182(15):1624-30.
3. Claesson U, Lassus A, Happonen H, et al. Topical treatment of venereal warts: A comparative open study of podophyllotoxin cream vs. solution. *Int J STD AIDS*. 1996 Oct;7(6):429-34.
4. Batista CS, Atallah AN, Saconato H, da Silva EMK. 5-FU for genital warts in non-immunocompromised individuals. *Cochrane Database of Systematic Reviews* 2010, Issue 4.
5. Bacelieri R, Johnson SM. Cutaneous warts: An evidence-based approach to therapy. *Am Fam Physician*. 2005 Aug 15;72(4):647-52.
6. Simonart T, Maertelaer VD. Systemic treatments for cutaneous warts: A systemic review. *J Dermatolog Treat*. 2010 Nov 6. [Epub ahead of print].

Product Monograph available upon request or at www.sanofi-aventis.ca.

Copyright © 2010 sanofi-aventis.
All rights reserved. sanofi-aventis Canada Inc.
Laval, Quebec H7L 4A8

DERMIK®

the dermatology division of sanofi-aventis Canada Inc.



CDN.CL110.09.02E 50094347

sanofi aventis
Because health matters