

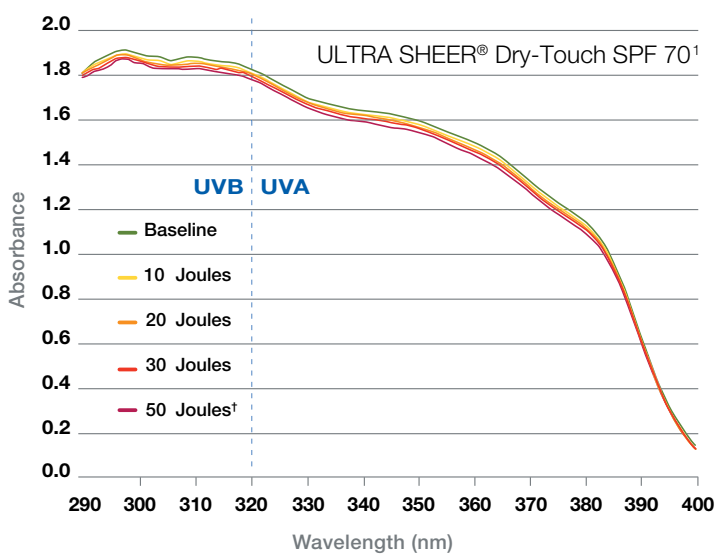
# Sun safety starts with science

HELIOPLEX® delivers innovative protection



HELIOPLEX®: A PROPRIETARY COMPLEX THAT STABILIZES AVOBENZONE.

Recommend NEUTROGENA® HELIOPLEX® sunscreen for broad spectrum, photostable UVA & UVB protection.



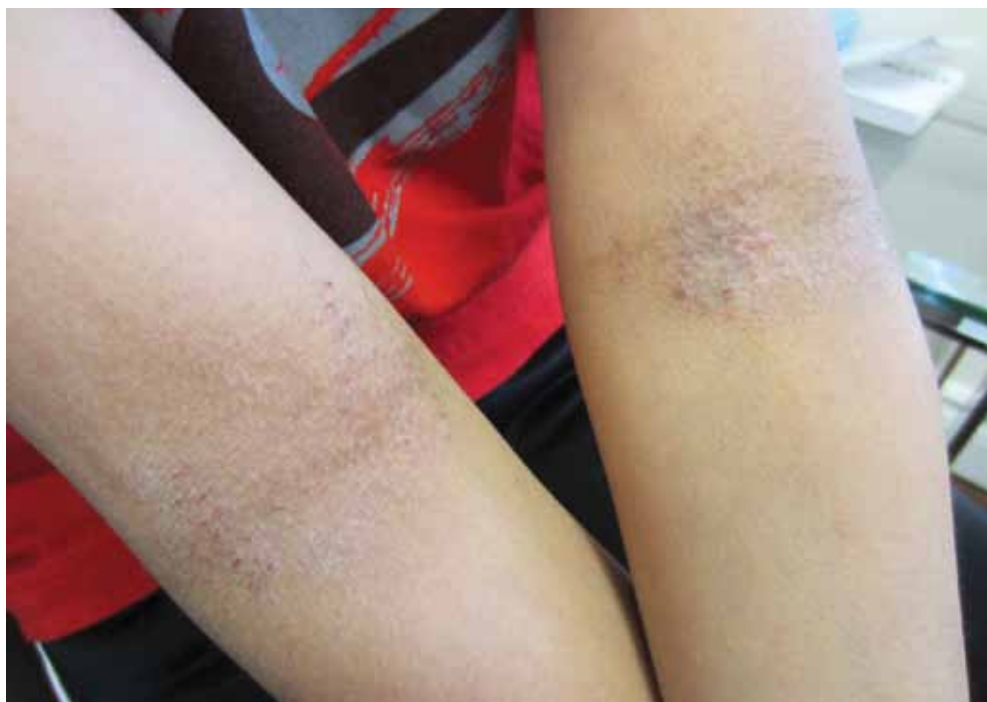1. Data on file. Johnson & Johnson Inc., Neutrogena.  
†Laboratory conditions representative of five hours of midday sun.

Neutrogena® SCIENCE & COMPLIANCE

## Tackling atopic dermatitis

Family counselling and a thorough management plan are needed for a pediatric disease that can persist into adulthood

BY DR. NICOLE HAWKINS, third-year dermatology resident at Dalhousie University & DR. BENJAMIN BARANKIN, medical director of the Toronto Dermatology Centre



Children and their parents should be advised that atopic dermatitis is a chronic disease that requires daily treatment complemented by lifestyle changes.

Atopic dermatitis is a chronic and relatively common skin condition that develops during the early years of life. It is characterized by pruritus and a relapsing course, and often is accompanied by a family history of eczema, allergies or asthma. Presentation varies widely, with the subsequent impact on quality of life varying from a minor nuisance to a major hindrance of physical activity, self-image and social interaction.

According to data from the International Study of Asthma and Allergies in Childhood (ISAAC) study, the prevalence of atopic dermatitis, or flexural eczema, in Canadian children ages six to seven years increased from 8.7% in 1994 to 12.0% in 2003 (see the *Journal of Allergy and Clinical Immunology*, April 2008). Globally, “a maximum prevalence plateau of around 20% suggests that there might be a finite number of persons susceptible to developing eczema in any population.”

Diagnostic criteria for atopic dermatitis were developed in

1994 by the U.K. Working Party and published in the *British Journal of Dermatology*. These remain the most extensively validated tool for diagnosing the disease. The main feature of the U.K. criteria is that a child must have history of perceived itch or a parental observation of scratching. This is in addition to three or more of the following: involvement of flexural skin creases; personal history of asthma or seasonal allergies; generally dry skin at any time in the last year; visible eczema in the flexural areas, extensor areas or cheeks in children younger than four years; and onset before two years of age.

That said, the clinical presentation of the disease varies throughout life. In the chapter on the disease in the highly respected *Dermatology* text (edited by Dr. Jean Bolognia et al.), the authors divide the clinical stages into infantile, childhood and adulthood.

The typical lesions of eczema include erythematous and edematous papules, sometimes with secondary excoriation and

crusting. Vesicles, usually deep-seated, can be seen in acute eruptions, and lichenification—exaggeration of the normal skin markings—is a feature in more chronic lesions. In infants, dry, erythematous and scaly patches are usually observed on extensor surfaces as well as the cheeks. These patches and plaques tend to spare the nasolabial folds.

In older children and adults, the clinical distribution changes to more commonly affect flexural surfaces, particularly the inner surface of the elbows and behind the knees. The most bothersome symptom of eczema is itch. Pruritus and the resultant scratching disturb sleep, daily function and social interaction, resulting in an overall decrease in quality of life.

Several studies have examined the effect of atopic dermatitis on quality of life. In their 2005 paper in *Pediatric Dermatology*, researchers at Wake Forest University in Winston-Salem, N.C., found there is “significant psychosocial burden in addition to

... the medical aspects of the disease.” They also noted that because atopic dermatitis is primarily a childhood disease, the condition affects caregivers and family members in addition to the patient.

The researchers noted the cost of the disease to society can range from \$100 to \$2,000 per patient per year, taking into account treatment regimens; household changes such as frequent dusting, removing carpets and switching detergents and soaps; and time off work to attend appointments. That is in addition to the psychosocial impact of the disease on the patient, worsened by the fact that affected areas of skin are on body parts (inner surfaces of elbows, backs of knees) exposed in certain types of clothing.

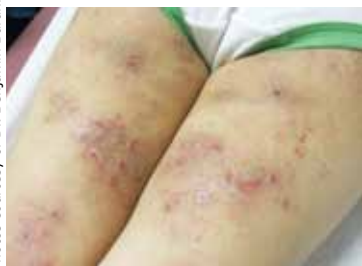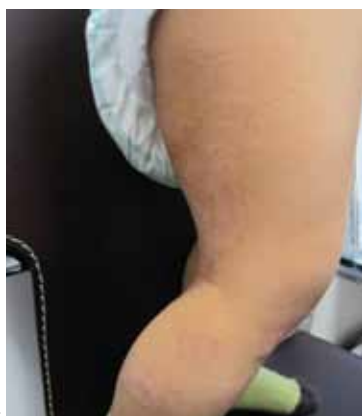The psychosocial and economic burdens of atopic dermatitis warrant a thorough management plan. These children and their parents should be counselled that atopic dermatitis is a chronic disease that for some children continues into adulthood. The need for maintenance and treatment on a daily basis—not only during flares—should also be addressed. Topical corticosteroids are the first-line treatment, complemented by lifestyle modifications.

The child should bathe daily, applying topical corticosteroid and emollient to his or her skin immediately following the bath to “lock in” moisture. Dust and allergens in the house should be minimized by regular dusting and vacuuming, especially in the child’s room; and household products such as clothing detergents should be unscented. Dryer sheets and fabric softeners should be avoided.

It is important to counsel parents on the importance of using topical steroids properly and regularly, especially because of misinformation on the Internet and from other sources, including other health professionals, warning of steroid atrophy. Parents and children should be reassured that when topical steroids are used in appropriate strength and applied as directed, atrophy is very unlikely. Going the extra step of demonstrating how much cream to use over a particular area while the patient is still in the office is also useful, as everyone has a different idea of the meaning of “apply liberally.” In general, a pea-sized amount of topical steroid can

cover an area the size of the palm of the hand.

Topical calcineurin inhibitors such as tacrolimus (Protopic) and pimecrolimus (Elidel) are useful steroid-free topical treatments for atopic dermatitis. They are good choices to manage eczema on thin-skinned areas such as the face, neck, armpits and groin. Some children find that these products sting or burn on initial application, but this effect seems to be ameliorated by regular use. In 2010, Health Canada approved tacrolimus



**Atopic dermatitis on the legs of a 21-month-old male (top) and a nine-year-old female.**

Photos courtesy of Dr. Benjamin Barankin

ointment once daily two days per week for maintenance therapy in moderate to severe atopic dermatitis.

In one phase III trial illustrating the benefits of a topical calcineurin inhibitor for disease control, Dr. Diamant Thaçi and colleagues at J.W. Goethe University in Frankfurt, Germany, enrolled 153 children ages two to 15 years with moderate to severe atopic dermatitis and randomly assigned them to 0.03% tacrolimus ointment or placebo twice weekly for 12 months. They found the drug reduced the number of flares and prolonged the time to first flare (146 versus 17 days). Additionally, tacrolimus showed economic benefit by ameliorating the cost to the patient and the health-care system of disease exacerbations.

A suitable regimen for a toddler with new onset of mild to moderate atopic dermatitis would be a daily bath in warm water, followed by a gentle patting dry. This should be immediately followed by appli-

cation of 1% hydrocortisone ointment to scaly, dry, and/or erythematous areas. After that, the entire body should be coated in a thick moisturizer. A hydrous emulsifying ointment is a good choice, as it is an excellent barrier cream and tends to be well-tolerated. However, some pediatric patients, particularly as they get older, find it to be quite thick and greasy.

For patients seeking alternatives, there are new ceramide-containing moisturizers. Ceramides are an important component of the natural lipid composition of the skin. Ceramide-containing moisturizers include the prescription Epi-Ceram and over-the-counter products such as Cetaphil Restoraderm and CeraVe.

The hydrocortisone ointment and emollient work best if applied twice daily, but the child need not be bathed for the second application.

For more significant or acute eczema, a stronger steroid preparation such as desonide or betamethasone valerate can be tried for a week or two to gain rapid control. The establishment of a routine early on in the disease can result in good clinical control and forms the basis of a regular skin care routine the child can follow for many years. Should this basic regimen fail to control the child’s atopic dermatitis, a referral to a dermatologist is appropriate.

The main complication of childhood eczema is secondary infection, either by bacteria or viruses. Infected lesions tend to appear more erythematous and inflamed, and feature the classic “honey-coloured crusting” seen in impetiginized eczema. Children with atopic dermatitis are more likely to be colonized by *Staphylococcus aureus* than children in the general population. Furthermore, this colonization is thought to aggravate the already inflamed skin. Thus, the practice of decolonization with bleach baths has arisen in the literature. An odd-sounding but simple practice, bleach baths have come back into vogue, and for good reason.

In one trial, Dr. Jennifer Huang and colleagues at Northwestern University in Chicago enrolled 31 patients, ages six months to 17 years, with moderate to severe atopic dermatitis and clinical signs of secondary bacterial infections.

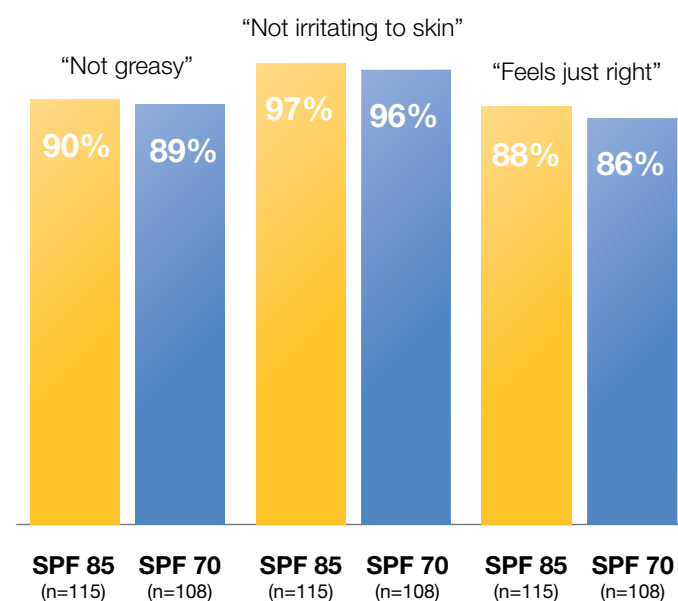
**continued on • page D9**

# Sun safety requires compliance

Patients say NEUTROGENA® “feels just right”!<sup>1</sup>



In a two-week blind preference study, ULTRA SHEER® formulations received high approval ratings.<sup>1</sup>



1. Data on file. Johnson & Johnson Inc., Neutrogena.

**Neutrogena**® SCIENCE & COMPLIANCE

**from • page D7**

All patients received oral cephalexin for 14 days and were randomized to receive intranasal mupirocin ointment and bleach (sodium hypochlorite) baths or intranasal petrolatum ointment and plain water baths for three months. The bleach concentration was approximately ½ cup of 6% bleach in a full bathtub of water. Patients were asked to bathe in the bleach or placebo bath for five to 10 minutes twice weekly.

At one and three months, patients who received both the bleach baths and intranasal mupirocin showed significantly greater mean reductions from baseline in Eczema Area and Severity Index scores compared with the placebo group, in particular at body sites other than the head and neck.

For patients in whom secondary bacterial infection is a problem, twice-weekly bleach baths are an inexpensive, practical and effective practice to complement an existing eczema care regimen.

Children with atopic eczema can also become secondarily infected with herpes simplex virus (HSV 1 or 2), resulting in eczema herpeticum—monomorphic vesicles or shallow ulcerations, usually rounded and crusted, appearing within or around existing areas of eczema. If infection is suspected, the area in question should be swabbed for bacterial culture and sensitivity, as well as HSV PCR. If bacterial infection is suspected, oral antibiotics in addition to topical medications are appropriate, as is a referral to a dermatologist if the diagnosis is uncertain. Similarly, if you suspect a patient has eczema herpeticum, oral antivirals in pediatric doses should be started, and a dermatologist's opinion sought.

The burden of skin disease is felt not only in its effect on the body, but also on the psyche of patients living with atopic dermatitis. The chronic nature of eczema makes it particularly impactful to a child, whose ability and willingness to participate in normal childhood activities can be limited by shyness, embarrassment and complications of the disease itself. Taking the time to educate the child and their family at diagnosis on the nature of the disease and the importance of flare and long-term management is paramount in the development of a healthy, happy child. **MP**

**References:**

**Brenninkmeier EE, Schram ME, Leeftang MM, et al.** Diagnostic criteria for atopic dermatitis: a systematic review. *Br J Dermatol.* 2008 Apr;158(4):754-65.

**Carroll CL, Balkrishnan R, Feldman SR, et al.** The burden of atopic dermatitis: impact on the patient, family and society. *Pediatr Dermatol.* 2005 May-Jun;22(3):192-9.

**Huang JT, Abrams M,**

**Tlougan B, et al.** Treatment of *Staphylococcus aureus* Colonization in Atopic Dermatitis Decreases Disease Severity. *Pediatrics.* 2009 May;123(5):e808-14.

Kalavala M, and Dohil MA. Calcineurin Inhibitors in Pediatric Atopic Dermatitis. *Am J Clin Dermatol.* 2011 Feb 1;12(1):15-24.

**Kang K, Polster AM, Nedorost AT, Stevens SR and Cooper KD (2003).** Atopic Dermatitis, in Bologna JL, Jorizzo JL, Rapini RP (Eds) *Dermatology*

2nd Edn. Philadelphia. Mosby Elsevier Science.

**Kircik LH, Del Rosso JQ.** Nonsteroidal treatment of atopic dermatitis in pediatric patients with a ceramide-dominant topical emulsion formulated with an optimized ratio of physiological lipids. *J Clin Aesthet Dermatol.* 2011 Dec;4(12):25-31.

**Thaçi D, Chambers C, Sidhu M, et al.** Twice weekly treatment with tacrolimus 0.03% ointment in children with atopic dermatitis: clinical efficacy and

economic impact over 12 months. *J Eur Acad Dermatol Venereol.* 2010 Sep;24(9):1040-6.

**Williams HC, Burney PG, Hay RJ, et al.** The U.K. Working Party's Diagnostic Criteria for Atopic Dermatitis I. Derivation of a minimum set of discriminators for atopic dermatitis. *Br J Dermatol.* 1994 Sep;131(3):383-96.

**Williams H, Stewart A, von Mutius E, et al.** Is eczema really on the increase worldwide? *J Allergy Clin Immunol.* 2008 Apr;121(4):947-54.e15.



### **i** Prescribing Summary

### **G** Patient Selection Criteria

Tacrolimus ointment, 0.03% and 0.1% (w/w)

#### **THERAPEUTIC CLASSIFICATION**

Topical Calcineurin Inhibitor

#### **INDICATIONS AND CLINICAL USE**

##### **Treatment**

PROTOPIC, both 0.03% and 0.1% for adults and only 0.03% for children aged 2 to 15 years, is indicated as a second-line therapy for short and long-term intermittent-treatment of moderate to severe atopic dermatitis in non-immunocompromised patients, in whom the use of conventional therapies are deemed inadvisable because of potential risks, or who are not adequately responsive to or intolerant of conventional therapies.

##### **Maintenance**

PROTOPIC is also indicated for maintenance therapy to prevent flares and prolong flare-free intervals in patients with moderate to severe atopic dermatitis experiencing a high frequency of flares (i.e., occurring 5 or more times per year) who have had an initial response (i.e., lesions cleared, almost cleared or mildly affected) with up to 6 weeks of treatment with twice daily PROTOPIC.

**Geriatric Use (≥ 65 years of age):** In Phase 3 studies, 405 patients ≥ 65 years old received PROTOPIC. The adverse event profile for these patients was consistent with that for other adult patients.

**Pediatric Use (2 to 15 years):** PROTOPIC, 0.03% strength only, is indicated for use in children aged 2 to 15 years. The safety and efficacy of PROTOPIC have not been established in pediatric patients below 2 years of age, and its use in this age group is not recommended.

#### **CONTRAINDICATIONS**

PROTOPIC (tacrolimus ointment) is contraindicated in patients with a history of hypersensitivity to tacrolimus or any other component of the preparation.

### **Hand** Safety Information

#### **WARNINGS AND PRECAUTIONS**

**Long-term safety of topical calcineurin inhibitors has not been established. Although a causal relationship has not been established, rare cases of skin malignancy and lymphoma have been reported in patients treated with topical calcineurin inhibitors, including PROTOPIC ointment 0.1% and 0.03%.**

**Therefore:**

• **Continuous long-term use of topical**

**calcineurin inhibitors including PROTOPIC ointment 0.1% and 0.03% should be avoided, and application limited to areas of involvement with atopic dermatitis.**

• **PROTOPIC ointment is not indicated in children less than 2 years of age. Only 0.03% PROTOPIC ointment is indicated for use in children 2-15 years of age.**

**General:** Prolonged systemic exposure to calcineurin inhibitors has been associated with an increased risk of infections, lymphomas and skin malignancies. These risks are associated with the intensity and duration of immunosuppression. Therefore, PROTOPIC should not be used in immunocompromised adults and children.

While a causal relationship has not been established, cases of skin malignancy and lymphoma have been reported in patients treated with topical calcineurin inhibitors, including PROTOPIC. The use of PROTOPIC should be avoided on pre-malignant and malignant skin conditions. Some malignant skin conditions, such as cutaneous T-cell lymphoma (CTCL), may mimic atopic dermatitis.

If signs and symptoms of atopic dermatitis do not improve within 6 weeks of twice daily treatment, PROTOPIC treatment should be discontinued and patients should be re-examined by their healthcare provider and their diagnosis be confirmed.

Patients should minimize or avoid natural or artificial sunlight exposure during the course of treatment, even while PROTOPIC is not on the skin. It is not known whether PROTOPIC interferes with skin response to ultraviolet damage.

**Carcinogenesis and Mutagenesis:** Prolonged use of calcineurin inhibitors for sustained immunosuppression in animal studies and systemic administration in transplant patients has been associated with an increased risk of lymphomas and skin malignancies. Although a causal relationship has not been established, cases of skin malignancy and lymphoma have been reported in patients treated with topical calcineurin inhibitors, including PROTOPIC, during post-marketing surveillance.

**Immune:** In clinical studies, cases of lymphadenopathy were reported and were usually related to infections and noted to resolve upon appropriate antibiotic therapy. The majority of these cases had either a clear etiology or were known to resolve. Transplant patients receiving immunosuppressive regimens (e.g. systemic tacrolimus) are at increased risk for developing lymphoma; therefore, patients who receive PROTOPIC and who develop lymphadenopathy should have the etiology of their lymphadenopathy investigated. In the absence of a clear etiology for the lymphadenopathy or in the presence of acute infectious mononucleosis, discontinuation of PROTOPIC should be considered. Patients who develop lymphadenopathy should be monitored to ensure that the lymphadenopathy resolves.

**Immunocompromised Patients:** The safety and efficacy of PROTOPIC in immunocompromised patients have not been studied.

**Renal Insufficiency:** Post-marketing cases of acute

renal failure have been reported in patients treated with PROTOPIC. Systemic absorption is more likely to occur in patients with epidermal barrier defects especially when PROTOPIC is applied to large body surface areas. Caution should also be exercised in patients predisposed to renal impairment.

**Sexual Function/Reproduction:** Reproductive toxicology studies were not performed with tacrolimus ointment.

**Skin:** The use of PROTOPIC may cause local symptoms of short duration, such as skin burning (burning sensation, stinging, soreness) or pruritus. Localized symptoms are most common during the first few days of PROTOPIC application and typically resolve as the lesions of atopic dermatitis heal.

PROTOPIC has not been studied for its efficacy and safety in the treatment of clinically infected atopic dermatitis. Patients with atopic dermatitis are predisposed to superficial skin infections. Treatment with PROTOPIC may be associated with an increased risk of varicella zoster virus infection (chickenpox or shingles), herpes simplex virus infection, or eczema herpeticum. In the presence of infections, the balance of risks and benefits associated with PROTOPIC use should be evaluated.

The enhancement of ultraviolet carcinogenicity is not necessarily dependent on phototoxic mechanisms. Despite the absence of observed phototoxicity in humans, PROTOPIC shortened the time to skin tumour formation in an animal photocarcinogenicity study. Therefore, it is prudent for patients to minimize or avoid natural or artificial sunlight exposure.

The use of PROTOPIC in patients with Netherton's syndrome is not recommended due to the potential for increased systemic absorption of tacrolimus. The safety of PROTOPIC has not been established in patients with generalized erythroderma.

#### **SPECIAL POPULATIONS**

**Pregnant Women:** There are no studies on the use of PROTOPIC in pregnant women.

Reproduction studies were carried out with systemically administered tacrolimus in rats and rabbits. Adverse effects on the fetus were observed mainly at oral dose levels that were toxic to dams. Tacrolimus at oral doses of 0.32 and 1.0 mg/kg during organogenesis in rabbits was associated with maternal toxicity as well as an increase in incidence of abortions. At the higher dose only, an increased incidence of malformations and developmental variations was also seen. Tacrolimus, at oral doses of 3.2 mg/kg during organogenesis in rats, was associated with maternal toxicity and caused an increase in late resorptions, decreased numbers of live births, and decreased pup weight and viability. Tacrolimus, given orally at 1.0 and 3.2 mg/kg to pregnant rats after organogenesis and during lactation, was associated with reduced pup weights. No reduction in male or female fertility was evident.

There are no adequate and well-controlled studies of systemically administered tacrolimus